

Immediate Loading of Implants in Bilateral Posterior Edentulous Space, A Case Report of 2 Years

Dr. Swapna Patankar¹, Dr. Rajesh Kshirsagar², Dr. Pratik Raut³, Dr. Amod Patankar⁴

¹Department Of Oral And Maxillofacial Pathology, Bharati Vidyapeeth Deemed University, Dental College And Hospital, Pune, Maharashtra, India

^{2,3,4} Department Of Oral And Maxillofacial Surgery, Bharati Vidyapeeth Deemed University, Dental College and Hospital, Pune, Maharashtra, India

Abstract : Case Report Focuses On Placement Of Immediately Loaded Implants In Posterior Edentulous Mandible Bilaterally. It Is Follow Up Study Of 2 Years. A Total Of 6 Immediately Loaded Mandibular Dental Implants Were Placed In Medically Compromised Patients. All Immediately Loaded Implants Were Torque Tested To More Than 30 Ncm. All Were Provisionally Restored In 24 Hrs. The Survival Rate For Immediately Loaded Implants Was 100%. Immediately Loaded Implants Have Predictable Clinical Success Along With Psychological And Esthetical Benefits To The Patient.

Keywords: Dental Implant, Functional Loading, Immediate Loading, Primary Stability

I. Introduction

Teeth have been replaced by various treatments but quality of life of patients has been changed due to high success rate of implants [1]. It is understood that replacement of an edentulous space with implants is the most natural replacement option. As less time is essential to regain esthetics and function after removing a tooth, immediate loading of implants has become popular [2,3].

II. Case Report

A 65 year old male patient reported with complaint of missing teeth in lower right and left back teeth region and difficulty in chewing due to same. Case history revealed that patient was hypertensive but under controlled with medications. Basic blood investigations and Cone Beam Computed Tomography (CBCT) were advised. Maxillary and mandibular casts were prepared in dental stone. With help of these records assessment of patient was done to obtain best results.

Written consent was taken. Standard sterilisation and asepsis protocol was followed. A full thickness mucoperiosteal flap was raised after administration of local anesthetic. Under-preparation of osteotomy site was done to achieve adequate primary stability. Six implants of size 4mm X 10mm (Osstem) were placed and implant stability was tested with a reverse torque of 30 Ncm. (Fig.1) Abutments were placed immediately. Flap was repositioned with sutures.

Intra Oral Periapical (IOPA) radiograph was taken immediately after to confirm the accurate positioning of implants. Provisional restorations were given to the patient within 24 hours. Three unit bridge of crowns was delivered at either side to distribute the occlusal load equally on all three implants.

Patient was followed up in outpatient department on regular basis. Radiographs were taken at definite interval. (Fig.2) Final prostheses with help of six separate crowns were placed 3 months after replacement of the provisional prostheses. (Fig.3) Orthopantomogram was repeated after 2 years. (Fig.4)

III. Discussion

Immediate loading is defined as placing the implants into functional occlusion within a period of 48 to 72 hours after insertion [4]. As demands by patients increased to reduce problems related to 2-stage procedures, the idea of immediate loading implants began to be considered [5, 6]. The mandible is considered ideal for immediate loading than the maxilla as it has better quality and quantity of bone [7]. It is more challenging in the maxilla than in the mandible due to esthetic concern. Primary implant stability is difficult to achieve in the maxilla as compared with the mandible, which is a "Gold standard factor" for immediate loading success [4].

Primary stability is defined as implant's capacity to withstand with loading forces in axial, lateral, and rotational directions [8]. Sennerby and Roos documented that; bone quality and quantity, implant design, and surgical technique are factors who determine primary implant stability [9]. As reported by Drago and Lazara, primary implant stability should be at least 30 Ncm (insertion torque) [10]. Numerous studies conducted by

various authors has shown that osseointegration has not been affected by loading time, whereas immediately loaded implants show bone-to-implant contact on histologic studies [11 - 13].

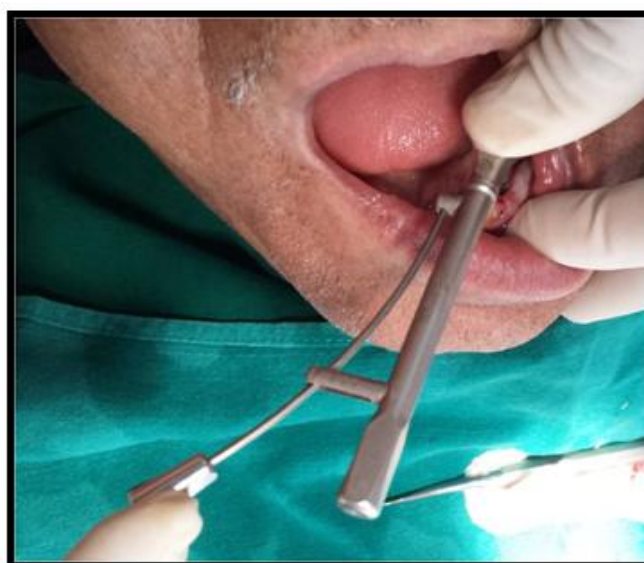Ericsson et al and Cannizzaro and Leone have shown 100% survival rate for the immediate loading implants replacing single-tooth. As reported by Henry and Liddelov, numerous clinicians support that soft tissue esthetics is improved with immediate loading implants as compared to a delayed approach [14].

IV. Conclusion

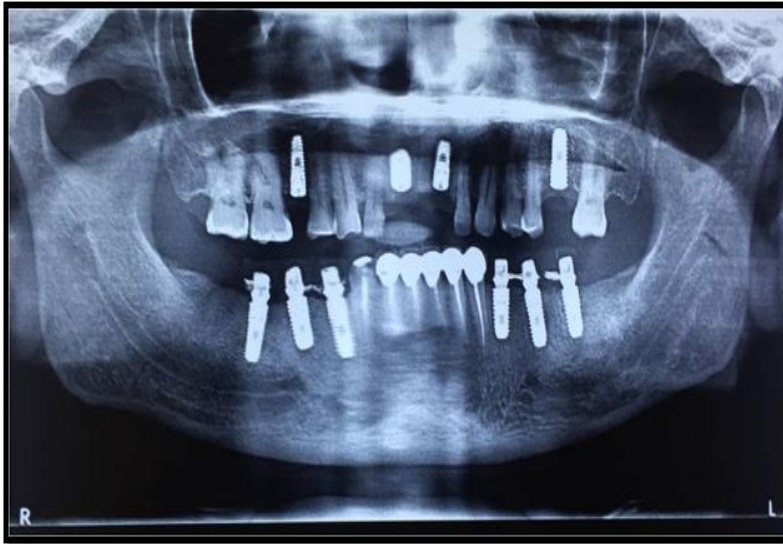If the bone quality and quantity is good immediate loaded implant can be considered as an option in old and medically compromised patients as it reduces treatment period, number of visits and at a same time gives psychological and esthetic benefit to the patient over 2-stage implant system.

References

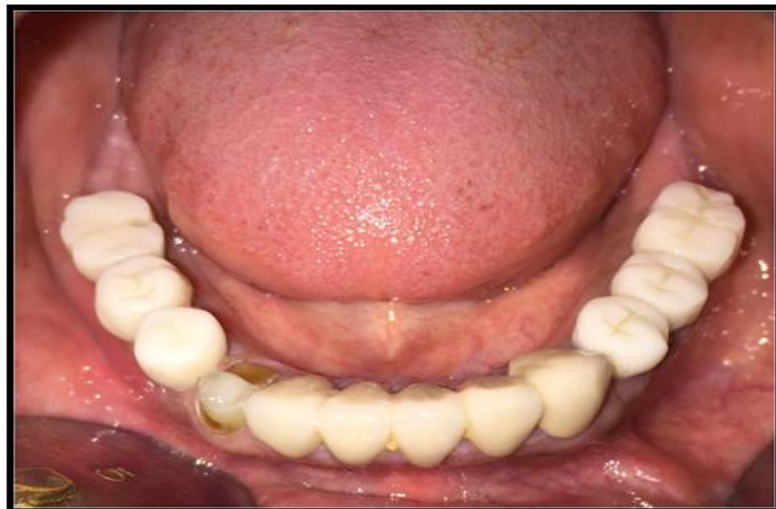- [1]. Laviv A, Levin L, Usiel Y et al, Survival of immediately provisionalized dental implants, A case-control study with up to 5 years follow-up, *Clin Implant Dent Relat Res* 12,e23, 2010
- [2]. Galli F, Capelli M, Zuffetti F et al, Immediate non-occlusal vs. early loading of dental implants in partially edentulous patients, A multicentre randomized clinical trial. Peri-implant bone and soft-tissue levels. *Clin Oral Implants Res* 19,546, 2008
- [3]. Sennerby L, Gottlow J, Clinical outcomes of immediate/early loading of dental implants, A literature review of recent controlled prospective clinical studies, *Aust Dent J* 53,S82, 2008
- [4]. Daniel Boedeker, John Dyer, Richard Kraut, Clinical Outcome of Immediately Loaded Maxillary Implants, A 2-Year Retrospective Study. *J Oral Maxillofac Surg* 69,1335-1343, 2011
- [5]. Degidi M, Nardi D, Piattelli A, Immediate loading of the edentulous maxilla with a final restoration supported by an intraoral welded titanium bar, A case series of 20 consecutive cases. *J Periodontol* 79,2207, 2008
- [6]. Ganeles J, Zollner A, Jackowski J, et al, Immediate and early loading of Straumann implants with a chemically modified surface (SLActive) in the posterior mandible and maxilla, 1-Year results from a prospective multicenter study. *Clin Oral Implants Res* 19,1119, 2008
- [7]. Collaert B, De Bruyn H, Immediate functional loading of TiOblast dental implants in full-arch edentulous maxillae, A 3-year prospective study. *Clin Oral Implants Res* 19,1254, 2008
- [8]. Ostman PO, Immediate / early loading of dental implants, Clinical documentation and presentation of a treatment concept, *Periodontol* 2008; 47, 90-112
- [9]. Stennerby L, Roos J, Surgical determinants of clinical success of osseointegrated oral implants, a review of the literature, *Int J Prosthodont* 1998; 11, 408-20
- [10]. Drago C, Lazzara RJ, Immediate occlusal loading of Osseotite implants in mandibular edentulous patients, a prospective observational report with 18- month data, *J Prosthodont* 2006; 15, 187-94
- [11]. Ghanavati F, Shayegh SS, Rahimi H et al, The effects of loading time on osseointegration and new bone formation around dental implants, A histologic and histomorphometric study in dogs. *J Periodontol* 77,1701, 2006 46
- [12]. Guida L, Iezzi G, Annunziata M, et al, Immediate placement and loading of dental implants, A human histologic case report, *J Periodontol* 79,575, 2008 47
- [13]. Romanos G, Testori T, Degidi M, et al, Histologic and histomorphometric findings from retrieved, immediately occlusally loaded implants in humans, *J Periodontol* 76,1823, 2005 48
- [14]. Tae Hyung Kim, Alena Knezevic, Michael Jorgensen, Sandra Rich, and Hessam Nowzari, Prospective, 1-year observational study of double-threaded tapered body dental implants with immediate loading, *The Journal Of Prosthetic Dentistry*, July 2015



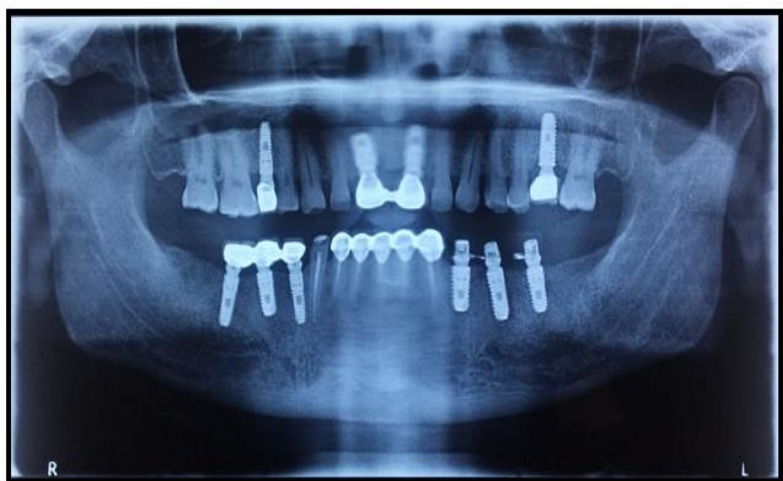
Implant stability was tested with a reverse torque of 30 Ncm.



Orthopantomogram was repeated after 3 months.



Final prostheses (6 separate crowns) were placed 3 months



Orthopantomogram was repeated after 2 years.